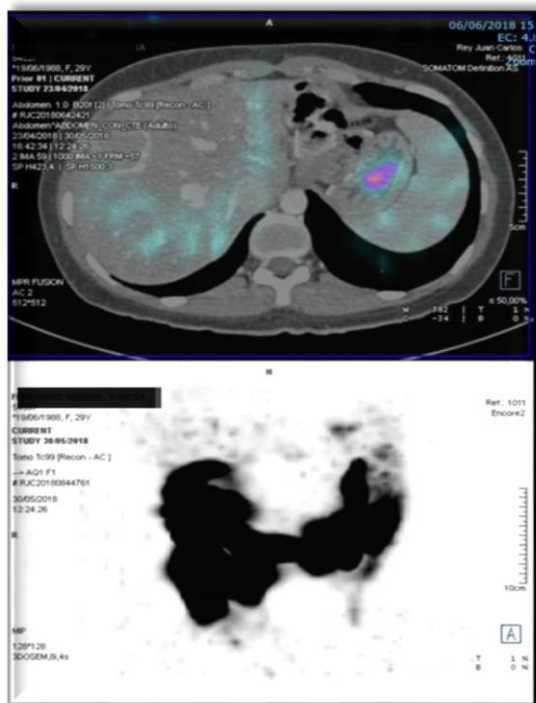


# + "PROTOCOLO DE ESTUDIO DE DOLOR POST BYPASSGÁSTRICO: *INTRODUCCIÓN DE LA GAMMAGRAFÍA HEPATOBILIAR EN EL ARSENAL DIAGNÓSTICO*"



# 4ª Reunión de Equipos de Cirugía Esofagogástrica y Obesidad de la Comunidad de Madrid y Zona Centro

## INNOVACIÓN ASISTENCIAL

29 de Noviembre de 2018 - Real Academia de Medicina - C/ Arrieta, 12 (Metro Ópera)

*Am J Surg.* 2011 June ; 201(6): 819–827. doi:10.1016/j.amjsurg.2010.05.007.

### **Abdominal Pain following Gastric Bypass: Suspects & Solutions**

Alexander J. Greenstein, MD, MPH and Robert W. O'Rourke, MD  
Department of Surgery, Oregon Health & Science University, Portland, OR

**Behavioral and nutritional disorders**

**Functional disorders**

**Biliary disease**

**Pouch-related disease**

**Small bowel-related disease**

**General diagnostic approach, conclusions**

# ***HIDA?***

# 4ª Reunión de Equipos de Cirugía Esofagogástrica y Obesidad de la Comunidad de Madrid y Zona Centro

## INNOVACIÓN ASISTENCIAL

29 de Noviembre de 2018 - Real Academia de Medicina - C/ Arrieta, 12 (Metro Ópera)



Surgery for Obesity and Related Diseases 5 (2009) 27–30

SURGERY FOR OBESITY  
AND RELATED DISEASES

Original article

### Bile reflux after Roux-en-Y gastric bypass: an unrecognized cause of postoperative pain

Daniel E. Swartz, M.D.<sup>\*</sup>, Elijah Mobley, M.D., Edward L. Felix, M.D.

*Advanced Bariatric Center, Fresno, California*

Received May 4, 2008; revised September 23, 2008; accepted October 13, 2008



Surgery for Obesity and Related Diseases 13 (2017) 1278–1283

SURGERY FOR OBESITY  
AND RELATED DISEASES

Original article

### Bile reflux of the remnant stomach following Roux-en-Y gastric bypass: an etiology of chronic abdominal pain treated with remnant gastrectomy

Erika La Vella, D.O.<sup>a,b,\*</sup>, Zach Hovorka, D.O.<sup>a,b</sup>, Donald E. Yarbrough, M.D.<sup>a</sup>,  
Elizabeth McQuitty, M.D.<sup>a,c</sup>

<sup>a</sup>*Samaritan Weight Management and Metabolic Surgery Institute, Corvallis, Oregon*

<sup>b</sup>*Department of Surgery, Western University College of Osteopathic Medicine Pacific Northwest, Corvallis, Oregon*

<sup>c</sup>*Department of Pathology, Good Samaritan Regional Medical Center, Corvallis, Oregon*

Received January 19, 2017; accepted April 6, 2017

*Obesity Surgery, 17, 414–415*

### Case Report

### Hepatobiliary Scintigraphy as a Diagnostic Modality for Gastroparesis of the Bypassed Stomach after Gastric Bypass for Morbid Obesity

Ahmad M. Tarakji, MD; Fermin Morales, MD; Peter Rovito, MD

*Department of Surgery, Lehigh Valley Hospital, Allentown, PA, USA*

“Noviembre 2012 hasta Noviembre 2018 **690**  
pacientes operados en nuestro centro”

- 2 pacientes con dolor post bypass gástrico en Y de Roux “peculiares”:
  - 1) 40 años, IMC: 46. BGYR 60/150. Cierre de espacios. NO colelitiasis. 28/08/2018 extirpación remanente.
  - 2) 25 años, IMC: 49.5. BGYR 100/150. 28/03/2014. 24/11/2015 cierre de espacios por dolor. 28/08/2018 extirpación remanente + colecistectomía.



*Buena evolución post operatoria,  
Resolución (por ahora) del dolor...*

**“CREEMOS”**

